International Journal of Paediatric Orthopaedics 2016 Sep-Dec;2(3):28-31

Changing trends in the management of Radial Club Hand. A review of the less commonly practiced and emerging techniques

Kapil Gangwal[1]

Abstract

Radial Club hand is a spectrum of deformities ranging from the mild to the severe grade. Mainstay of treatment for several years has been centralization procedures with soft tissue balancing. Villki's microvascular toe transfer, Watari's 2nd ray transfer, and Paley's ulnarization are some of the attempts for overcoming the shortcomings with centralization procedures. This is a brief description of the techniques which have evolved over the years and appear promising in managing this particularly vexing problem.
Keywords: Radial Club Hand, Metatarsophalangeal joint tranfer, Vilkki's procedure

Introduction

Radial longitudinal deficiency is a spectrum of disorders ranging from mild shortening of the forearm to the severe, where there is a complete absence of radius. According to the Bayne and Klug classification system, which subdivides club hand into types I through type IV, type III and IV are the most severe variants and also the most commonly encountered subtypes. [1]

Mainstay of management of this condition has been centralization of the ulna over the carpus. Various modifications of the centralization technique have been described over the years and this still continues to be the most widely practiced method to date.

Centralization procedures have not been without problems, and have shown to be associated with significantly high rates of recurrence of deformity. There is also a risk of iatrogenic injury to the distal ulnar physis which predisposes to further reduction of forearm growth in the already short limb. [2,3,4].

Numerous innovative techniques have emerged over the years to overcome the shortcomings with the centralization technique. Vilkki's Microvascular toe transfer, Tsuge and Watari's transfer of the 2nd ray of the hand, and Paley's Ulnarization procedure are particularly attractive in their conception towards overcoming the problems and drawbacks with the commonly performed centralization procedure. This is a brief description of the techniques which have evolved over the years and appear promising in managing this particularly vexing problem.

[1]Santokba Durlabhji Memorial Hospital cum Medical Research Institute, Jaipur. Rajasthan. India.

Address of Correspondence
Dr Kapil Gangwal
Paediatric Orthopaedic Surgeon & Honorary Consultant Orthopaedics, Santokba Durlabhji Memorial Hospital cum Medical Research Institute, Jaipur. Rajasthan. India
Email: kapil67@hotmail.com


Dr. Kapil Gangwal

Vascularized Metatarsophalangeal Joint Transfer

Simo K. Vilkki form Finland, described an innovative method of overcoming some of the shortcomings of previously tried reconstruction methods in 1992. He used a vascularised second metatarsophalangeal joint transfer for stabilization of the carpus and preventing recurrence of radial deformity and volar subluxation of wrist. [5]

Vacularized metatarsophalangeal joint transfer procedure was based on various studies which included experimental microvascular metatarsophalangeal joint transfers in canines. [6]

Epiphyseal growth following vascularised metatarsophalangeal joint transfer in pediatric joint injuries has been well documented following toe transfer for the adactylous hand. [7]

The metatarsal and proximal phalanx are transferred to the forearm to create a Y construct which stabilizes the carpus while maintaining growth potential at both the limbs of the Y. This type of a Y construct to stabilize the wrist had been described by Albee in 1928 and Starr in 1945 but both these attempts were with non-vascularized grafts. [8,9].

Surgery is indicated for Bayne type III and IV club hands as well as failed centralizations procedures. It is contraindicated in children who are unable to flex the elbow, Children who have very poor quality of fingers, forearm muscles and with severe radial deviation of wrist of over 90 degrees. [10]

The procedure is best performed between 2.5 to 4 years of age. The delay is to allow adequate size of metacarpal to be able to hold the distractor device which needs to stay in place for several months. [10]

As preparation for the operation the family is encouraged to stretch and splint the deformity. For children with absent thumb a pollicisation procedure is advocated. This is best done within the first or second year of life, when the child begins to start pinching with the index and middle fingers.

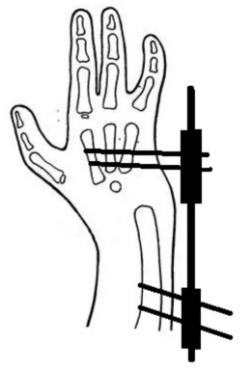

Figure 1: Fixator application on ulnar aspect of forearm

Figure 2: . Final position of wrist after the consolidation of transfer

Figure 3: Appearance of foot after healing

The procedure entails performing a soft tissue release in severe cases and application of a distractor device to create space for accepting the transfer of the MTP joint. The distraction device is placed on the ulnar aspect and is parallel to the ulnar border. The radial aspect of the forearm is kept free to provide space for transfer of the metatarsal in the second stage of the procedure [Fig. 1]. About 25 mm distraction is needed to accommodate the transfer. This typically takes around 50 days of distraction. The MTP transfer is performed once adequate distraction has been achieved. Two teams work simultaneously. One team prepares the recipient area while the other harvests the graft. The entire 2nd ray is harvested along with the flexor and extensor tendons and the skin. The middle and distal phalanx are discarded. The filleted skin is retained and used to cover the defect on the radial side of the wrist after transfer. While closing the defect in the foot, it is important to suture the inter-metatarsal ligament to prevent splaying of the toes [10] [Fig. 3]. The MTP joint construct is placed on the radial side extending from the metaphyseal flare on the ulna to the base of the second metacarpal. A notch is created in the base of the metacarpal to accept the distal aspect of the transfer and likewise a 20 mm cortical flap is created on the radial aspect of the ulna proximal to the metaphyseal flare to accept the proximal part of the MTP joint transfer.

The proximal and distal site of the MTP transfer is fixed with K wires which are bent and left outside the skin on the ulnar side, or optionally under the skin on the bone and removed at a later date.

Once the bone and the tendons have been fixed and repaired respectively, the arterial anastamosis is done. This is accomplished by end to end attachment to the radial artery or the median artery. Additional anastamosis can be done to the ulnar artery which is an end to side anastamosis. Finally, the skin is inset and sutured and the distraction device is locked in place. A bulky dressing is applied to the forearm, and the foot is casted for 4 weeks. The K- wires are removed at 4 – 6 weeks and the distraction device is removed at 8 -9 weeks at time of bony consolidation of the transfer [Fig. 2]. The limb is casted after removal of the distractor to allow for bony consolidation [10].

In Vilkki's series of 19 wrists treated by this technique the average radial deviation was 28 degrees, wrist motion averaged 83 degrees, ulnar growth averaged 15.4 cm, and was 67% of the contralateral side. There was some loss of correction of radial deviation over time and averaged 12 degrees over 15.2 years. Complications included fracture of MTP joint in 2 patients, arterial failure in 3 patients, delayed union at ulnar side in 2 patients, and pseudoarthrosis of the MTP joint in 2 patients. 2 children required ulnar osteotomies for bowed ulna and 3 children required lengthening of the transfer for inadequate growth. Donor site morbidity was also documented, which included hallux valgus in 1, scarring in 2, and occasional pain in 1. [11]

The procedure is technically demanding and requires expertise with micro-vascular anastomosis technique. Results are encouraging with respect to wrist motion, maintenance of wrist position and growth of the limb following reconstruction.

Tsuge Watari

Kenya Tsuge and Shoichi Watari from the University of Hiroshima presented a unique method of managing congenital aplasia of radius in 1985. They combined the procedure of pollicisation of the index finger with simultaneous correction of the radial club hand deformity by a novel approach.

Observations were based on treatment of two children with this technique. One child was 2 yr. 11 months old and the other was 6 yrs. at surgery. [12]

Prerequisite for the procedure is adequate flexion of the elbow. Preoperative angiography is performed to ascertain adequacy of vascular anatomy and circulation of the digit prior to embarking on the procedure.

Incision is similar to Buck Gramco's incision for pollicisation but extending proximally around the radial aspect to the dorsum of the forearm [Fig. 4].

Pollicisation is performed as per the Buck Gramco technique, except that the technique involves transfer of the index finger metacarpal along with its periosteum, trapezoid, as well as the vascular pedicle and flexor tendons. The metacarpal is pushed into the forearm towards the radial aspect of ulna between the flexor and extensor tendons, to a point where the metacarpophalangeal joint rested at the level of the carpometacarpal joint [Fig. 5]. The digit is repositioned to oppose the middle finger and fixed to the third metacarpal with a K – Wire. The metacarpophalangeal joint capsule is sutured to

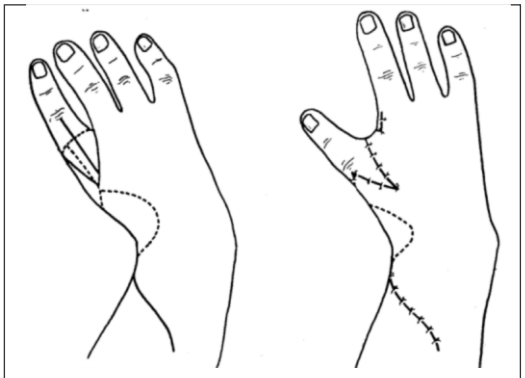

Figure 4: Incision for Tsuge Watari Procedure

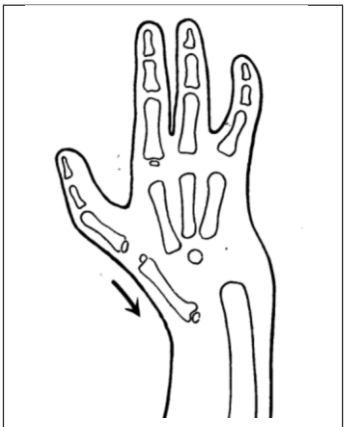

Figure 5: Final Position after transfer

the adjoining carpometacarpal capsule to provide stability.

Osteotomy of ulna can be performed to allow for better correction of the deformity especially in older children. The metacarpal base was not fixed to the ulna.

The procedure is particularly attractive in its conception as the two procedures required for the correction of the radial club hand are combined into a single stage. There is no interference with the growth of the distal ulna, which is a major hitch with the centralization procedures. There is structural support on the radial aspect making a Y shaped construct which helps in preventing recurrence of deformity. [Fig. 5].

Unanswered questions as to efficacy of the procedure are due to lack of long term studies. It is not clear if growth potential of the transferred metacarpal will match that of the other metacarpals or the distal ulnar growth. The ulnar bump is still visible and may appear cosmetically unacceptable. The procedure involves transfer of the second digit on its vascular pedicle and is technically demanding as well as subject to vascular complications. Incidence of recurrence of deformity is unclear as follow up on cases was short in their published report.

Ulnarization

This is a technique of reconstruction of the radial club hand described by Paley. It has been practiced at their institution since 1999 and published recently in 2015. The treatment strategy is designed to overcome the two paramount issues with treatment of Radial Club Hand which are recurrence of deformity and growth arrest of the distal ulna. The procedure is based on the principles of the Buck Gramco's Radialization technique with some modifications. [14]

The term Ulnarization has been used instead of Radialization, as the carpus is translocated to the ulnar aspect of the ulna. By convention of nomenclature the carpus is thus ulnarized rather than radialized which indicates movement of the ulna in relation to the carpus, which is contrary to the common norms of nomenclature in orthopaedics. [14]

Ulnarization technique is particularly attractive as transferring the carpus on the ulnar aspect of the ulna has several mechanical advantages towards maintaining correction of the deformity. [Fig. 1]. First, the ulnar head on the radial side of the carpus functions as a fulcrum across which the radial muscles can contract and prevent recurrence of deformity. Second, the ulnar head on the radial aspect of the carpus works as a mechanical block and prevents the carpus from drifting radialy. Third, the transfer of the FCU to the dorsum of the wrist, makes it an extensor, and puts the finger flexors at a mechanical advantage for working. Finally, the length of the forearm is increased as a subsequent separate procedure, thus increasing the flexor muscle length allowing for better force generation. [14]

The procedure is performed at or after 1year age. The carpus is acutely transferred to the ulnar side of the wrist. Reconstruction of the thumb is done 6 months after the reconstruction of the club hand. Lengthening of the forearm is done at 8 and 14 years of age. [13]

An extensile volar zig zag incision is utilized [Fig. 2]. The FCU is exposed and lifted off with its attachment to the pisiform. The abductor digiti minimi is released from the pisiform. The ulnar nerve is decompressed in the Guyon's canal. The FCR is often rudimentary, and is divided, along with its fibrous anlage when present.

A radial pocket is created on the radial aspect of the carpus. The ulnar ligaments and capsular attachments are released from the ulnar side staying close to the carpus. A volar capsultomy is performed from the ulnar to the radial side [Fig. 3]. It's important to preserve the vascular pedicle of the distal ulna which comes from its radial aspect.

The carpus is then transferred on to the ulnar aspect of the ulna making the ulna lie in the radial pocket that was created earlier. The transfer of the ulna head to the radial aspect also reduces the tension on the vascular pedicle which is coming from the radial side. [Fig. 4].

The ulna is transfixed to the carpus with K-wires. [Fig. 5]. The FCU is transferred to the dorsal aspect of the carpus around the base of fourth metacarpal with the attached pisiform, to allow for bone to bone healing. The K – wires are removed after 3 months. [13]

In Paley's series the children had an average passive dorsiflexion of 36^0 and 9^0 of active movement. There were no recurrences of deformity and none of the cases had growth arrest of the distal ulna. [14]

Overall this has shown to be a safe technique with no recurrences no growth arrest, improved grip strength, and improved cosmes

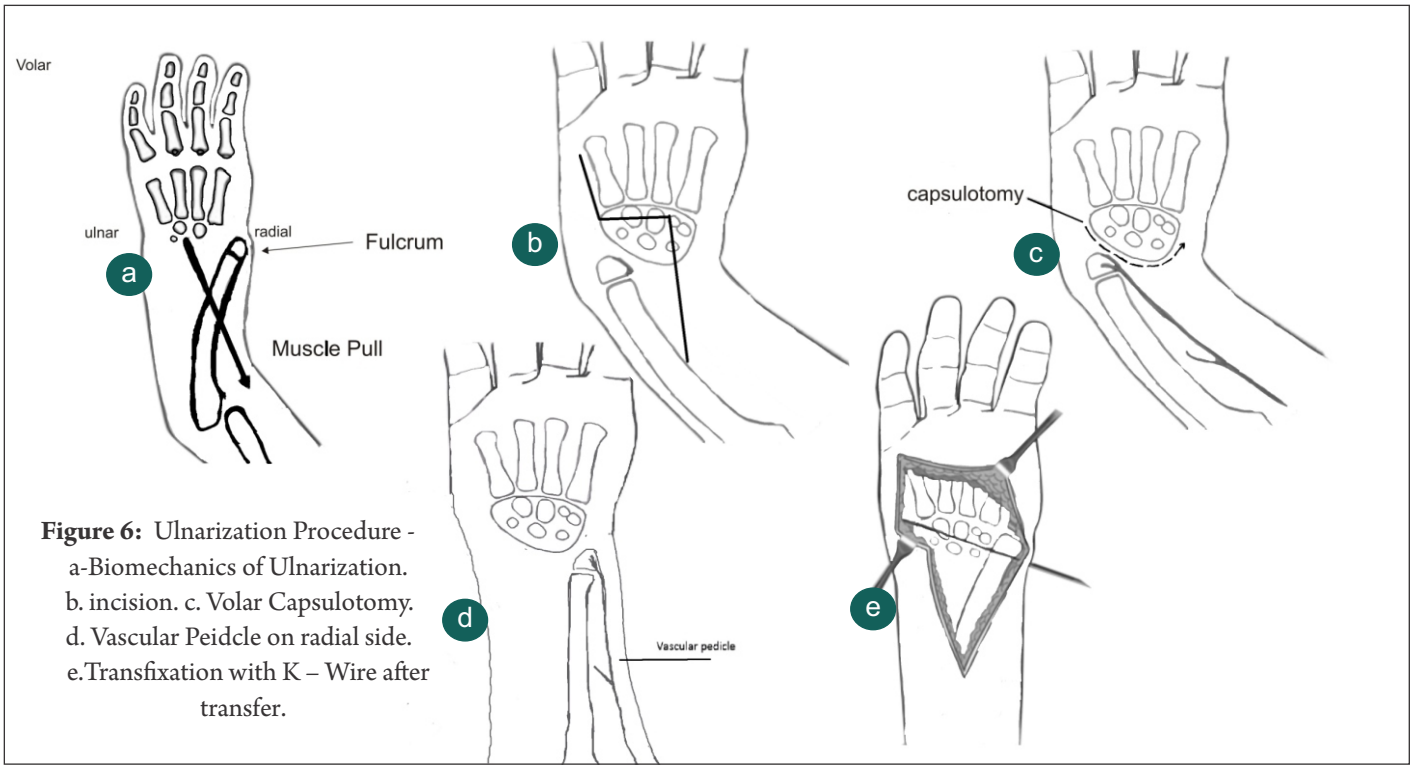

Figure 6: Ulnarization Procedure - a-Biomechanics of Ulnarization. b. incision. c. Volar Capsulotomy. d. Vascular Peidcle on radial side. e.Transfixation with K – Wire after transfer.

Conclusions

Various techniques have emerged which attempt to overcome the problems of recurrence of deformity and injury to the distal ulnar physis seen frequently with the centralization procedures. Vilkki's microvascular toe transfer is currently the preferred technique for reconstruction of the radial club hand but requires expertise with microvascular reconstruction techniques which restricts its universal applicability. Paley's ulnarization is an ingenious technique which assures to provide lasting correction of deformity as well as continued growth of the forearm. The technique and approach is more in the gamut of the general orthopaedic surgeon and presents to be the most viable option for surgeons not familiar with microvascular reconstruction technology. Tsuge Watari procedure requires more study and analysis to its efficacy, and its application is limited until long term outcomes are available.

References

1. Bayne LG, Klug MS. Long-term review of the surgical treatment of radial deficiencies. J Hand Surg Am. 1987;12(2):169–179.

2. Shariatzadeh H, Jafari D, Taheri H, Mazhar FN. Recurrence rate after radial club hand surgery in long term follow up. J Res Med Sci. 2009;14(3):179–186.

3. McCarthy JJ, Kozin SH, Tuohy C, Cheung E, Davidson RS, Noonan K. External fixation and centralization versus external fixation and ulnar osteotomy: the treatment of radial dysplasia using the resolved total angle of deformity. J Pediatr Orthop. 2009;29(7):797–803.

4. Goldfarb CA, Klepps SJ, Dailey LA, Manske PR. Functional outcome after centralization for radius dysplasia. J Hand Surg Am. 2002;27(1):118–124.

5. Vilkki SK. Distraction lengthening and microvascular bone transplantation in the treatment of radial club hand. In: Canadell J, Ferial F, Lazo-Zbikowski J, editors. Proceedings of the 14th International Hoff man External Fixation Conference; Pampolona, Spain: EUROGRAF; 1992. pp. 249–251.

6. Heikel HV. Aplasia and hypoplasa of the radius: studies on 64 cases and on epiphyseal transplantation in rabbits with the imitated defect. Acta Orthop Scand Suppl. 1959;39:1–155

7. Sestero AM, Van Heest A, Agel J. Ulnar growth patterns in radial longitudinal deficiency. J Hand Surg Am. 2006;31(6):960–967.

8. Albee FH. Formation of radius congenitally absent: condition seven years after implantation of bone graft. Ann Surg. 1928;87(1):105–110.

9. Starr DE. Congenital absence of the radius: a method of surgical correction. J Bone Joint Surg Am. 1945;27(4):572–577.

10. de Jong JP1, Moran SL, Vilkki SK..Changing paradigms in the treatment of radial club hand: microvascular joint transfer for correction of radial deviation and preservation of long-term growth. Clin Orthop Surg. 2012 Mar;4(1):36-44

11. Vilkki SK. Vascularized metatarsophalangeal joint transfer for radial hypoplasia. Semin Plast Surg. 2008;22(3):195–212.

12. Tsuge K, Watari S. New surgical procedure for correction of club hand. J. Hand Surg Br. 1985 Feb;10(1):90-4

13. Ulnarization as treatment of Radial Clubhand (RCH). Paley D, Robins C A. Limb Lengthening and Reconstruction Surgery Case Atlas.1-11. 2015

14. Ulnarization of Radial Clubhand Video Presentation. Limb lengthening.us. http://limblengtheningdoc.org/ulnarization_for_radial_clubhand.html. Sept. 2014

Conflict of Interest: NIL
Source of Support: NIL

How to Cite this Article

Gangwal K. Changing trends in the management of Radial Club Hand. A review of the less commonly practiced and emerging techniques. International Journal of Paediatric Orthopaedics Sep-Dec 2016;2(3):28-31.