Review Article

POSI
IJPO


Dr. Sandeep Patwardhan


Dr. Arkesh Madegowda


Dr. Sujith Omkaram


Dr. Pavan Patil


Dr. Ashok Shyam


Dr. Parag Sancheti

Address of Correspondence
Dr. Arkesh Madegowda,
Clinical Fellow, Department of Paediatric Orthopaedics
Sancheti Institute for Orthopaedics and Rehabilitation,
Pune, Maharashtra, India.
E-mail: dr.arkesh@gmail.com

[1]Department of Paediatric Orthopaedics
Sancheti Institute for Orthopaedics and Rehabilitation,
Pune, Maharashtra, India.

DOI- 10.13107/ijpo.2022.v08i02.137 | www.ijpoonline.com

Overcorrection as Complication of Growth Modulation with Eight-Plate for Coronal Plane Deformities of Knee and its Management

Sandeep Patwardhan MS Ortho[1], Arkesh Madegowda MS Ortho[1], Sujith Omkaram MS Ortho[1], Pavan Patil MS Ortho[1], Ashok Shyam MS Ortho[1], Parag Sancheti MS Ortho[1]

Abstract

Objectives: To report the incidence of overcorrection as complication following eight-plate application for genu varum/valgum deformities and its management.

Methods: This was a retrospective review of children who underwent growth modulation for genu varum/valgum between 2012-2019. Data of patients who had presented with overcorrection of their primary deformity, the reasons for such complication and its management were collected and analysed.

Results: 110 children had undergone growth modulation during the study period. 75 children (68%) had achieved deformity correction in mean time of 14.4 months and had their implant removed on time when intercondylar (ICD)/intermalleolar (IMD) distance was ≤ 5 centimeters (cms) and /or Hip Knee Ankle (HKA) angle was < $\pm 6^0$. 29 children (26%) were lost to follow up. 6 children (5.4%) had presented with overcorrection of moderate to severe grade with mean ICD/IMD of 13.3 cms (range 11-18) and mean HKA angle of 14.3^0 (range $11\text{-}21^0$). Mean age of initial surgery was 6.1 years (range 5-8). Mean time gap of presentation with overcorrection was 33.6 months (range 24-45). Lack of awareness, long distance of hospital, medical expenses were some of the notable reasons for irregular follow-up. All 6 had an open physes with growth remaining when they presented with overcorrection. These children managed with repeat growth modulation. Final correction was achieved at mean time of 15.3 months and underwent implant removal. At the latest follow up of 4.4 years, limb alignment within physiologic limits was maintained.

Conclusion: Children undergoing growth modulation should be carefully monitored with regular follow-up to avoid complication of overcorrection. Overcorrection beyond physiologic limits can be managed with repeat growth modulation in younger children with open physes.

Keywords: Growth modulation, Genu valgum, Genu varum, Irregular follow up, Complication, Overcorrection.

Introduction

Growth modulation functions by tethering one side of the growing physis, thereby allowing differential growth to correct angular deformities of knee in younger children [1]. Staples, transphyseal screws and eight-plates are the various implant options available for guided growth. Eight-plates are the preferred choice for growth modulation surgery because of ease of its application, faster correction, reversible nature of epiphysiodesis and lesser complications related to hardware failure [2-5]. Close follow up is an important aspect of treatment protocol as correction needs to be monitored at regular intervals and implants are to be removed once the deformity is corrected. If implants are retained for too long, it can result in overcorrection of the deformity when the physis is active in young children. This may need additional

Submitted: 11/01/2022; Reviewed: 27/01/2022; Accepted: 10/05/2022; Published: 10/08/2022

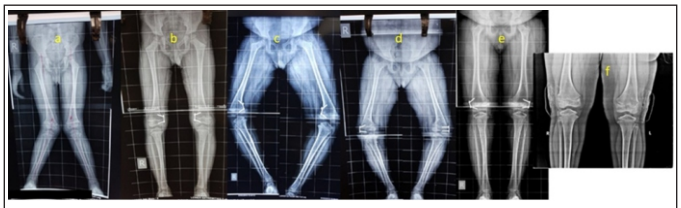

Figure 1: Radiograph of a child presented with bilateral genu valgum as initial deformity (a), underwent growth modulation of distal femur at 6 years of age (b), presented with overcorrected genu varum deformity (c), underwent repeat growth modulation (d), achieved deformity correction after 20 months of second surgery (e), radiograph of both knees following implant removal (f).

surgeries to correct opposite deformities [6, 7]. Very few studies in the literature have discussed in detail about the complication of overcorrection in growth modulation surgery and its management [5-8]. The purpose of this study was to report our experience of overcorrection as complication of growth modulation for coronal plane deformities of knee, its causes and approach to managing such complication..

Materials and methods

This is a retrospective study of patients who underwent growth modulation with eight-plate for correction of genu valgum or varum deformities. After institutional ethics board approval, patient electronic medical records from 2012-2019 were reviewed. Data of patients who had presented with significant overcorrection following growth modulation to our centre were collected and analyzed. A detailed clinical history and examination was performed in children presented with varum or valgum deformities of knee. For genu varum, intercondylar distance (distance between two medial femoral condyles) was

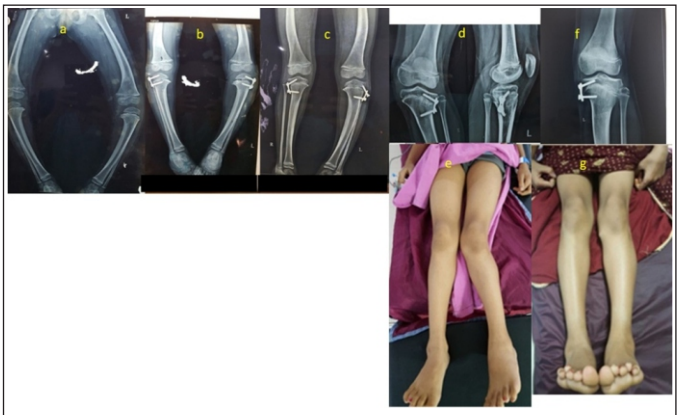

Figure 3: Scanogram of a 5 y old child with bilateral genu varum deformity (a), had undergone growth modulation of proximal tibia (b), presented with implant back out of left side with residual varus deformity at 9 months follow up (c), underwent reapplication of eight-plate on lateral aspect of proximal tibia physis and implant removal on right side, presented with left sided genu valgum (d, e), achieved deformity correction after 18 months (f, g).

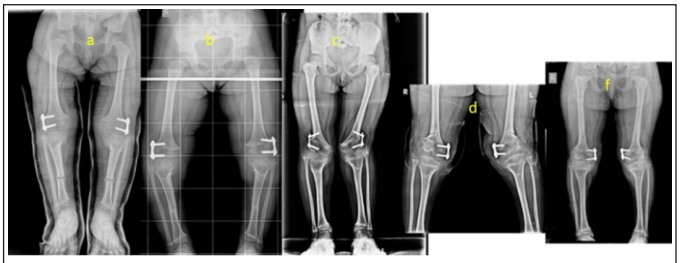

Figure 2: Radiograph of a child presented with bilateral genu varum with tibial intorsion who underwent growth modulation of distal femur with bilateral derotation osteotomy (a), 3 months follow up radiograph showing healed osteotomy (b), presented with overcorrected genu valgum after 38 months of initial surgery (c), repeat growth modulation was performed (d), deformity correction was obtained in 13 months time (e).

noted in supine position with patella facing upward and ankles just touching each other. For genu valgum, intermalleolar distance (distance between two medial malleoli) was measured in supine position with knees just touching each other with patella pointing upwards [9]. Standing lower limb scanogram with patella facing forward was taken preoperatively and during follow-ups to look for mechanical axis angulation. Radiographically, mechanical axis of lower limb was measured as angle between mechanical axis of femur (centre of femoral head to centre of knee joint) and mechanical axis of tibia (centre of tibial spine to centre of ankle mortise). This angle is also known as Hip Knee Ankle (HKA) angle. The normal HKA angle is 0 ± 3^0 [10]. In valgus deformity, the mechanical axis is displaced laterally and the HKA angle becomes negative. In varus deformity, the mechanical axis is displaced medially and the angle becomes positive [10, 11]. The deformities are considered to be within physiologic limits when ICD is ≤ 5 cms in children up to 3 years for genu varum and IMD of ≤ 7 cms in children up to 4 years of age for genu valgum [12, 13]. Surgical treatment was given to patients aged more than 4 years with persistent deformities, with IMD/ICD more than 10 cms and/or HKA angle more than 10° [14]. The deformity is said to be overcorrected beyond physiologic limits when ICD/IMD is > 10 cm in the opposite direction.

The contact details of patients who were lost to follow up with retained implants were also retrieved and attempts were made to contact them to enquire current status of their knee deformity, whether plates are still in place or removed elsewhere. Patients were asked to send their standing clinical photograph with both patellae facing forward to evaluate deformity correction. They were also requested to attend the outpatient clinic for detailed clinical and radiological evaluation to look for any overcorrection.

Results

A total of 110 children had undergone growth modulation for

Table 1: Clinical details and outcome assessment of children included in the study

Patient no	Initial deformity	Age at primary surgery (years+ months)	Sex (M/F)	Etiology	Time gap of presentation with opposite deformity (months)	HKA angle of overcorrection (degrees)	IMD/ICD of overcorrection (centimeters)	Time for final deformity correction (months)
1	Genu valgum (B/L)	7	F	Idiopathic	28	12	12	11
2	Genu varum (B/L)	6	M	Rickets	24	11	13	18
3	Genu valgum (B/L)	8	M	Rickets	35	21	18	20
4	Genu varum(B/L)	5	F	idiopathic	32	14	11	12
5	Genu varum with tibial in-torsion(B/L)	6	M	Skeletal dysplasia	38	12	15	13
6	Genu varum (B/L)	5	F	Rickets	45	16	11	17

(B/L- Bilateral, M-male, F-female, HKA- Hip Knee Ankle, IMD- Intermalleolar distance, ICD-Intercondylar distance)

genu valgum or varum correction during the study period. 29 children (26%) were lost to follow up. Out of remaining 81, 75 children had their implants removed on time following deformity correction (IMD/ ICD ≤ 5 cms and/or HKA angle≤ 6^0). 6 children had presented with significant overcorrection of their original deformity during the study period. 2 of these had bilateral genu valgum, 4 children had bilateral genu varum as primary deformities for which initial growth modulation surgery had been undertaken. 3 were males and 3 were females. Mean age was 6.1 years (range 5-8) when they underwent first eight-plate insertion. The etiology of these deformities were idiopathic in 2 patients; 3 were due to rickets and 1 due to skeletal dysplasia (Table 1).

Mean time gap of presentation with overcorrection following index surgery was 33.6 months (range 24-45). All children had overcorrection of moderate to severe grade with mean ICD/IMD of 13.3 cms (range 11-18) and HKA angle of 14.3^0 (11-21). As there was minimum of 2 years of skeletal growth remaining with open physes, these children were treated with implant removal and reapplication of 8 plate on the opposite end of the physis in the same sitting. Patients were followed up every 3 months and correction monitored with clinical examination and standing hip to ankle scanogram. Mean time taken for final correction was 15.1 months (range 11-20). All 6 children underwent implant removal when ICD/IMD was ≤ 5cms and/or HKA angle ≤ 6^0. At the latest mean follow up of 4.4 years (range 2-8), normal limb alignment was maintained (Figure 1, 2, 3).

It also prompted us to check our data for children who were lost to follow-up and any occurrence of overcorrection in them. It showed 26% children (29 out of 110) were lost to follow up with retained implants. When we attempted to contact these patients, 14 of them (12.7%) were untraceable. Their final deformity correction could not be evaluated. 5 patients had their implants still in place and had reached skeletal maturity without complications. 10 patients had their implant removal at a different centre.

Discussion

Growth modulation surgery is a safe and an efficient method to treat angular deformities of knee but it needs careful preoperative planning and appropriate follow up to avoid complications such as under or overcorrection [1, 5, 14]. A mild overcorrection is recommended to address the rebound phenomenon and avoid relapse of deformity in children with high growth potential but the line between this and pathological over correction is not clearly defined in the literature [7, 15]. The recommended treatment for mild overcorrection is observation and for moderate to severe overcorrection, repeat growth modulation or corrective osteotomy is advised [14].

Zajonz et al [7] reported 3 cases of overcorrection (out of 198 eight plate implantations for genu valgum) as complication due to lack of compliance to follow up. 2 of these patients underwent corrective osteotomy as growth was complete at the time of review with the opposite deformity. Vaishya et al16 reported 2 cases of overcorrection which gradually corrected on subsequent follow up in their series of 24 children with genu valgum. Kemppainen et al [6] in their study of incomplete follow ups and its associated complications in 200 children treated with eight-plate, noted 4 cases of overcorrection in 23 children (17.3%) who were lost to follow up with retained implants. 2 of these children underwent corrective osteotomies to remedy their overcorrection.

The rate of overcorrection complication in our study was 5.4% and it was attributable to irregular follow-up. Greater distance from home to the hospital, lack of awareness of possible overcorrection, medical expenses, associated medical comorbidities and lack of a formal referral system were some of the noted reasons contributing to irregular follow-ups in our series. All 6 children had moderate to severe grade of overcorrection when they presented to our clinic after the period of loss to follow up. Following radiological confirmation of open physes and minimum 2 years of growth remaining, these children were offered repeat growth modulation to correct their opposite deformities. It was also noted that a

significant proportion of children (14 out of 110, 12.7%) were lost to follow up with retained implants with whom contact could not be established. It is not known whether any of these children had overcorrection as 9 of these children had more than two years of growth remaining when eight-plates were applied.

The current study reiterates the importance of appropriate follow-up and timely implant removal to avoid complication of overcorrection. Proper counselling and hazards of inadequate follow-up have to be explained to the parents during the preoperative counselling. Parents and families have to be stressed about the need of implant removal at appropriate time during every follow-up. Whenever possible, maintenance of a separate growth modulation registry and notifying those parents/families who fail to come for follow-up after specified time period may prevent these adverse events. To the best of our knowledge, this is the first study describing overcorrection and its management in detail in younger children with open physes who underwent growth modulation surgery.

There are some limitations of our study. It is a retrospective study with a small sample size. Longer follow up till skeletal maturity is ideal in these children to monitor for any recurrence of deformity. There are no case examples who might need corrective osteotomy due to completion of skeletal growth for rectifying overcorrection in our series.

Conclusion

Children undergoing growth modulation surgery should be carefully monitored with regular follow-up to avoid overcorrection. The surgeon should take an active role in educating parents regarding the importance of timely follow up and the necessity for implant removal following complete correction of the deformity. Pathological overcorrection can be managed with repeat growth modulation using eight plate in younger children with open physes.

References

1. Saran N, Rathjen KE. Guided growth for the correction of pediatric lower limb angular deformity. J Am Acad Orthop Surg. 2010 Sep;18(9):528-36.

2. Stevens PM. Guided growth for angular correction: a preliminary series using a tension band plate. J Pediatr Orthop. 2007 Apr-May;27(3):253-9.

3. Danino B, Rödl R, Herzenberg JE, Shabtai L, Grill F, Narayanan U, Segev E, Wientroub S. Guided growth: preliminary results of a multinational study of 967 physes in 537 patients. J Child Orthop. 2018 Feb 1;12(1):91-96. doi: 10.1302/1863-2548.12.170050.

4. Radtke K, Goede F, Schweidtmann K, Schwamberger T, Calliess T, Fregien B, Stukenborg-Colsman C, Ettinger M. Temporary hemiepiphysiodesis for correcting idiopathic and pathologic deformities of the knee: A retrospective analysis of 355 cases. Knee. 2020 Jun;27(3):723-730.

5. Kumar S, Sonanis SV. Growth modulation for coronal deformity correction by using Eight Plates-Systematic review. J Orthop. 2018 Feb 2;15(1):168-172

6. Kemppainen JW, Hood KA, Roocroft JH, Schlechter JA, Edmonds EW. Incomplete Follow-up After Growth Modulation Surgery: Incidence and Associated Complications. J Pediatr Orthop. 2016 Jul-Aug;36(5):516-20.

7. Zajonz D, Schumann E, Wojan M, Kübler FB, Josten C, Bühligen U, Heyde CE. Treatment of genu valgum in children by means of temporary hemiepiphysiodesis using eight-plates: short-term findings. BMC Musculoskelet Disord. 2017 Nov 15;18(1):456.

8. Lawing C, Margalit A, Ukwuani G, Sponseller PD. Predicting Late Follow-up and Understanding Its Consequences in Growth Modulation for Pediatric Lower Limb Deformities. J Pediatr Orthop. 2019 Jul;39(6):295-301.

9. Gupta P, Gupta V, Patil B, Verma V. Angular deformities of lower limb in children: Correction for whom, when and how? J Clin Orthop Trauma. 2020 Mar-Apr;11(2):196-201.

10. De Brauwer V, Moens P. Temporary hemiepiphysiodesis for idiopathic genua valga in adolescents: percutaneous transphyseal screws (PETS) versus stapling. J Pediatr Orthop. 2008 Jul-Aug;28(5):549-54.

11. Degreef I, Moens P, Fabry G. Temporary epiphysiodesis with Blount stapling for treatment of idiopathic genua valga in children. Acta Orthop Belg. 2003;69(5):426Y432.

12. Heath CH, Staheli LT. Normal limits of knee angle in white children–genu varum and genu valgum. J Pediatr Orthop. Mar-Apr 1993.

13. Saini UC, Bali K, Sheth B, Gahlot N, Gahlot A. Normal development of the knee angle in healthy Indian children: a clinical study of 215 children. J Child Orthop. 2010 Dec;4(6):579-86.

14. Masquijo JJ, Artigas C, de Pablos J. Growth modulation with tension-band plates for the correction of paediatric lower limb angular deformity: current concepts and indications for a rational use. EFORT Open Rev. 2021 Aug 10;6(8):658-668.

15. Chang FM, Ma J, Pan Z, Hoversten L, Novais EN. Rate of correction and recurrence of ankle valgus in children using a Transphyseal medial malleolar screw. J Pediatr Orthop. 2015;35:589–592.

16. Vaishya R, Shah M, Agarwal AK, Vijay V. Growth modulation by hemi epiphysiodesis using eight-plate in Genu valgum in Paediatric population. J Clin Orthop Trauma. 2018 Oct-Dec;9(4):327-333.

Declaration of patient consent : The authors certify that they have obtained all appropriate patient consent forms. In the form, the patient has given the consent for his/her images and other clinical information to be reported in the journal. The patient understands that his/her names and initials will not be published and due efforts will be made to conceal their identity, but anonymity cannot be guaranteed.

Conflict of interest: Nil; **Source of support:** None

How to Cite this Article

Patwardhan S, Madegowda A, Omkaram S, Patil P, Shyam A, Sancheti P | Overcorrection as Complication of Growth Modulation with Eight-Plate for Coronal Plane Deformities of Knee and its Management | International Journal of Paediatric Orthopaedics | May-August 2022; 8(2): 06-10.