Innovative Technique

POSI
IJPO

# Combined Hemiepiphysiodesis Using Tension Band Plate and Osteotomy for Severe Coronal Plane Deformities Around Knee Joint in Children with Skeletal Dysplasia – An Innovative Technique

Anil Agarwal MS Ortho[1], Ankit Jain D Ortho[1], Ravi Jethwa MS Ortho[1], Jatin Raj Sareen MS Ortho[1]

Dr. Anil Agarwal

Dr. Ankit Jain

Dr. Ravi Jethwa

Dr. Jatin Raj Sareen

**Address of Correspondence**
Dr. Anil Agarwal
Department of Paediatric Orthopaedics, Chacha Nehru Bal Chikitsalaya, Delhi, India.
**E-mail:** rachna_anila@yahoo.co.in

[1]Department of Paediatric Orthopaedics, Chacha Nehru Bal Chikitsalaya, Delhi, India.

DOI- https://doi.org/10.13107/ijpo.2022.v08i02.139


## Abstract

Skeletal dysplasia in children is sometimes associated with severe coronal plane angulations around the knee. The associated ligament laxity adds to the complexity of surgical correction. Osteotomies require precise surgical planning and execution. Hemiepiphyseodesis is usually employed only in mild and moderate deformity. Distraction osteogenesis method is labour intensive, costly and requires a prolonged treatment course. We describe an innovative surgical technique which combines hemiepiphysiodesis using tension-band plates and a metaphyseal osteotomy. The technique utilises acute bony correction by osteotomy followed by residual correction, if any and soft tissue fine tuning through growth modulation. Growth modulation also addresses recurrence to some extent. The surgical technique is described along with illustrative case examples.

**Keywords:** Skeletal dysplasia, Osteotomy, Hemiepiphyseodesis

## Introduction

There are several skeletal dysplasias encountered in children. Although they are characterized by distinctive features, there is a generalized disorder of bone and cartilage growth. As a result, structural malformations can occur in many regions. The knee is one region where such angular deformities are frequently manifested. Long standing involvement can lead to severe deformity.

Angular deformities around the knee in skeletal dysplasia have several peculiarities. Bone quality may be inferior due to osteopenia. The epiphysis and adjacent growth plate can be misshapen, smaller in size and may not have normal physiological growth potential. The deformity at the knee may be a combined effect of femoral and tibial involvement. As the angulation becomes severe, the ligaments may give way adding to the instability. Some dysplasias have associated inherent tissue laxity as well. Ligamentous laxity exaggerates the overall deformity and in severe cases, activities are curtailed and the child may become non ambulatory.

Surgical planning for deformity correction of severe angular deformities in skeletal dysplasia is often studded with complex calculations for bony and soft tissue components. Frequently, surgical correction runs the risk of under/over correction or recurrence [1]. We describe an innovative surgical technique which combines hemiepiphysiodesis using tension-band plates and a metaphyseal osteotomy. The technique utilizes benefits of acute bony correction by osteotomy followed by residual correction, if any and soft tissue fine tuning by growth modulation. The growth modulation also takes care of recurrence to some extent.

Submitted: 23/04/2022; Reviewed: 20/05/2022; Accepted: 11/06/2022; Published: 10/08/2022

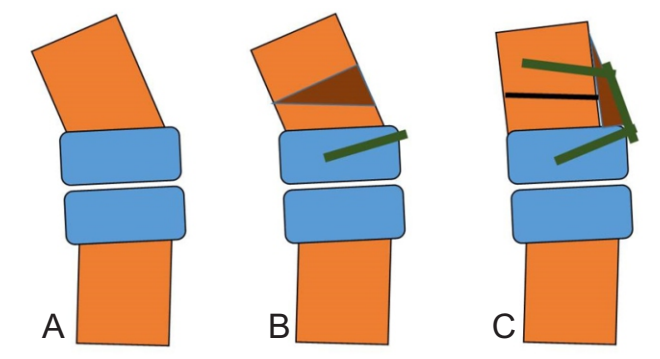


**Figure 1:** Pictorial representation of combined technique of eight plate hemiepiphysiodesis and metaphyseal osteotomy: (A) Severe coronal plane angulation around knee region (B) The distal screw along with plate is secured to the distal femoral epiphysis. Wedge decided on template planning is removed about 1 cm proximal to the physeal plate (C) The wedge is placed base down over the step created by the osteotomy and '8' plate is applied across the osteotomy site.


**Figure 3:** Case example 1: A 10 year old boy with Ollier disease and severe angulations in both knees. The ligament laxity component is illustrated in figure 2 above: A, B, preoperative clinical photographs and standing scanogram C, Postoperative radiographs. Note the step created by closure of the narrower proximal femoral segment over the wider distal metaphyseal segment. The proximal screw of '8' plate was secured over the wedge graft. An additional '8' plate was used in view of changes in proximal tibia D, Radiographs at 2 months showing united osteotomy sites. Patient was full weight bearing by this time E, F, Sixteen months post procedure, the ligament laxity was balanced and slight overcorrection was achieved. The plates were removed at this time G, H, I, Follow up at 28 months post procedure. Some valgus recurrence is obvious. Preserved knee movements. The child is under supervised follow up.

## Technique

The site of deformity is ascertained by careful clinical and radiological examination. A template planning for a closed wedge osteotomy is performed. Any rotational misalignment is also accounted for in the planning. Planning of rotational malalignments typical requires multiple axial cuts on a full


**Figure 2:** Ligament laxity associated with angular deformities: (A) The non weight bearing and (B) weight bearing photographs showing the component of ligament laxity in both limbs especially right side.

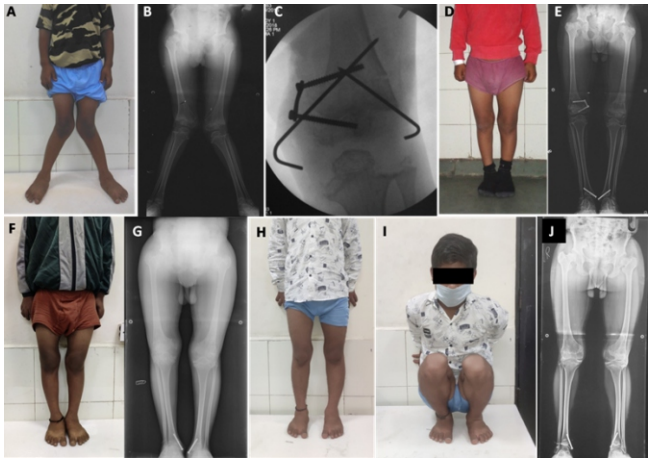


**Figure 4:** Case example 2: A, B, 9 year child with spondyloepiphyseal dysplasia and severe coronal plane deformities of both knee regions C, Postoperative radiographs. Osteotomy stabilized with two 2.5 mm Kirschner wires. '8' plate fixation across the osteotomy site D, E, Six months later, the plate of left side was removed after achieving slight overcorrection F, G, Right side plate was removed 6 months later following correction on this side also H, I, J, Follow up 36 months post procedure. Preserved knee movements. Deformity correction largely maintained even during growth spurt of the child.

lower extremity computer tomography (CT) study [2]. Femoral torsion is measured between a line through the femoral neck and a line adapted to the posterior contour of the femoral condyles. Tibial torsion is measured between a line adapted to the posterior contour of the tibial head and the intermalleolar axis. Although, both valgum and varus deformities can exist, the following description is for a femoral valgus deformity (Figure 1). The estimated wedge (closing wedge) to be resected from the medial cortex of femur should be just sufficient or slightly less to correct mechanical axis of the limb passing through the knee joint. The distal medial femur is approached through a medial incision. The vastus medialis is reflected and periosteum is incised and retracted. The distal screw and '8' plate are secured on the medial femoral epiphysis. At this time, the screw is not fully tightened to permit alignment of the plate at a later stage. An osteotomy is planned 1 cm

proximal to the physeal plate. The planned wedge is removed from the medial femoral cortex. The osteotomy is closed and stabilized with 2.5 mm Kirschner wires. The ends of the wires are left protruding out for easy removal as an outpatient. The triangular wedge removed is placed base down over the step created by apposition of the wider distal and a narrower proximal femur. The proximal screw of '8' plate along with plate is then fastened through the graft into the femoral cortex. The lower screw is secured now, further compressing the osteotomy site.

The osteotomy site is protected in an above knee cast for 5 weeks. At completion of splintage, a radiological evaluation is performed for union and the wires removed thereafter. The knee is mobilized through range of movement exercises, quadriceps strengthening and gradual weight bearing is permitted. No further splintage or bracing is advised. The child normally progresses to full weight bearing over a few weeks. The operated limb may not be fully aligned immediately postoperatively. The acute correction offered by the osteotomy, however, permits easy weight bearing. The child is kept under supervised follow up with 3 monthly standing scanograms. The '8' plate is removed when ligament laxity is gradually compensated and slight overcorrection is achieved.

Two illustrative case examples are discussed in Figure 2, 3 and 4.

**Discussion**

Although the principles of managing angular deformities are similar to other conditions, there are several challenges in skeletal dysplasias. Besides medical conditions, spinal abnormalities, anaesthesia complications, the bone size, quality and the abnormal physis restrict the treatment options. Ligamentous laxity adds to the complexity of surgical planning.

Proximal tibial or distal femoral osteotomies are commonly used depending upon the site of deformity [3, 4]. Displacement or rotational corrections are added while performing the osteotomy. Neurovascular complications, iatrogenic fractures and compartment syndromes are described as complications following acute corrections [5]. Moreover, recurrence is very common in young children, especially if there is under correction. Ligament laxity can further obscure the result of successful procedure.

Gradual correction using hemiepiphysiodesis is another tool in the armamentarium of the clinician for the management of angular deformities in skeletal dysplasia [3, 6, 7]. Some dysplasias are associated with extremely slow growth and in such patients this method becomes unreliable [8]. Growth plates seldom work effectively when the deformity is severe (> 20 degrees) [8, 9].

Gradual correction can also be achieved by various types of external fixators (monolateral, Illizarov or modifications) [10, 11]. The implant and surgical cost, expertise required, and the prolonged treatment course make this application restricted to select institutions. Needless to mention, the course of distraction osteogenesis is frequently studded with pin tract infections, readjustments, regeneration issues and requirement of additional surgeries [3].

The combined use of acute osteotomy and hemiepiphysiodesis with '8' plates utilizes the best of two treatment modalities for correction of severe coronal plane angulations associated with skeletal dysplasias. Combined procedures lessen the anaesthesia and surgical risks which are common encountered in these conditions. With the technique described, no translation is deemed necessary. We prefer closing wedge osteotomies to protect neurovascular structures. Lesser corrections can be accepted if found risking these structures. The intact periosteal sleeve of the far cortex serves as the stabilizing tether preventing osteotomy instability. The metaphyseal osteotomy is fairly stable with the spanning '8' plate and Kirschner wires and no further implants are necessary. The metaphyseal screw of the tension-band plate is intentionally kept longer than epiphyseal screw for better bony purchase. The osteotomy, being performed close to the metaphysis, requires smaller wedges and healing occurs quickly. The wedge provides additional cancellous graft which can be added to the osteotomy site.

The acute correction provides the child with a relatively aligned limb permitting early ambulation. Precise and complex surgical planning is unnecessary as the residual deformity is corrected over time through hemiepiphysiodesis. The tension-band plate works better as the physeal plate post-osteotomy is more horizontal and better subject to longitudinal loading. An added advantage of the combined procedure is for the management of ligament laxity, often associated with severe angulation. The ongoing gradual correction can reshape the deformed epiphysis and adjusts for the ligament laxity. The tension-band plates can be retained as long as they maintain the deformity correction. They can be removed once slight overcorrection is obvious.

Complications related to osteotomy and hemiepiphyseodesis can be minimized by careful surgical planning. Our technique is less invasive to perform compared to single stage large corrections and more forgiving in terms of accepting residual deformity. There can be recurrences if the technique is performed in young children with several years of growth remaining. If the child is kept under supervised follow up, recurrences can be dealt with through minor surgical procedures. The combined technique can provide several fruitful years of useful mobility for a child with severe coronal angulation.

**Conclusion**

The combined use of acute osteotomy and hemiepiphysiodesis with tension-band plates is a less invasive method for correction of severe coronal plane angulation associated with skeletal dysplasia. The technique utilizes the benefits of acute correction by osteotomy followed by residual soft tissue fine tuning by growth modulation. The technique offers a safety margin for under correction, may prevent neurovascular complications associated with acute correction of severe angular deformity, while addressing the issues of ligamentous laxity and recurrence.

## References

1. Bassett GS. Orthopaedic aspects of skeletal dysplasias. Instr Course Lect. 1990;39:381-387.

2. Rosskopf AB, Buck FM, Pfirrmann CW, Ramseier LE. Femoral and tibial torsion measurements in children and adolescents: comparison of MRI and 3D models based on low-dose biplanar radiographs. Skeletal Radiol. 2017;46:469-476.

3. Thacker MM, Davis ED, Ditro CP, Mackenzie W. Limb lengthening and deformity correction in patients with skeletal dysplasias. In: Sabharwal S (eds.). Pediatric Lower Limb Deformities. Springer, Cham; 2016.

4. Bell DF, Boyer MI, Armstrong PF. The use of the Ilizarov technique in the correction of limb deformities associated with skeletal dysplasia. J Pediatr Orthop. 1992;12:283-290.

5. Pinkowski JL, Weiner DS. Complications in proximal tibial osteotomies in children with presentation of technique. J Pediatr Orthop. 1995;15:307-312.

6. Yilmaz G, Oto M, Thabet AM, Rogers KJ, Anticevic D, Thacker MM, Mackenzie WG. Correction of lower extremity angular deformities in skeletal dysplasia with hemiepiphysiodesis: a preliminary report. J Pediatr Orthop. 2014;34:336-345.

7. Cho TJ, Choi IH, Chung CY, Yoo WJ, Park MS, Lee DY. Hemiepiphyseal stapling for angular deformity correction around the knee joint in children with multiple epiphyseal dysplasia.

8. Shabtai L, Herzenberg JE. Limits of growth modulation using tension band plates in the lower extremities. J Am Acad Orthop Surg. 2016;24):691-701.

9. Masquijo JJ, Artigas C, de Pablos J. Growth modulation with tension-band plates for the correction of paediatric lower limb angular deformity: current concepts and indications for a rational use. EFORT Open Rev. 2021;6:658-668.

10. Bell DF, Boyer MI, Armstrong PF. The use of the Ilizarov technique in the correction of limb deformities associated with skeletal dysplasia. J Pediatr Orthop. 1992;12:283-290.

11. Myers GJ, Bache CE, Bradish CF. Use of distraction osteogenesis techniques in skeletal dysplasias. J Pediatr Orthop. 2003;23:41-45.

**Declaration of patient consent :** The authors certify that they have obtained all appropriate patient consent forms. In the form, the patient has given the consent for his/her images and other clinical information to be reported in the journal. The patient understands that his/her names and initials will not be published and due efforts will be made to conceal their identity, but anonymity cannot be guaranteed.

**Conflict of interest:** Nil **Source of support:** None

How to Cite this Article

Agarwal A, Jain A, Jethwa R, Sareen JR | Combined Hemiepiphysiodesis Using Tension Band Plate and Osteotomy for Severe Coronal Plane Deformities Around Knee Joint in Children with Skeletal Dysplasia – An Innovative Technique | International Journal of Paediatric Orthopaedics | May-August 2022; 8(2): 20-23.