

Case Series



POSI
IJPO



Dr. Njalalle Baraza



Dr. Mordicai Ating'a

Address of Correspondence

Dr. Njalalle Baraza,

Department of Trauma and Orthopaedics, Aga Khan University, 3rd Parklands Avenue, P.O. Box 30270, GPO 00100, Nairobi, Kenya

E-mail: njaleb@doctors.org.uk

¹Department of Trauma and Orthopaedics, Aga Khan University, 3rd Parklands Avenue, P.O. Box 30270, GPO 00100, Nairobi, Kenya

DOI- <https://doi.org/10.13107/ijpo.2025.v11.i01.232>
www.ijpoonline.com

This is an Open Access journal, and articles are distributed under the terms of the Creative Commons Attribution

Non-Commercial-Share Alike 4.0 License

(<http://creativecommons.org/licenses/by-nc-sa/4.0>)

which allows others to remix, tweak, and build upon the work non-commercially as long as appropriate credit is given and the new creation are licensed under the identical terms.

Varus Derotation Osteotomy of the Proximal Femur in Neuromuscular Children Using a Locking Plate - Surgical Technique and Initial Results

Njalalle Baraza^{FRCS (Tr & Orth)}¹, Mordicai Ating'a^{FRCS (Tr & Orth)}¹

Abstract

Introduction: Hip dysplasia affects up to 33% of children with neuromuscular disease. The main objective of treatment is improvement of femoral head coverage. Depending on the severity of dysplasia, treatment required may range from casting in abduction to salvage procedures including excision arthroplasty. The most commonly employed surgical procedure is a varus derotation osteotomy (VDRO) which is usually undertaken using a fixed angle blade plate, with or without a pelvic osteotomy. Unfortunately these implants are not always available. We therefore developed a novel technique using a locally available locking reconstruction plate to perform VDRO surgery, and present our initial results following the use of this technique.

Methods: Six hips in four patients of GMFCS IV or V suffering from hip dysplasia were included in the study. Pre and postoperative Reimers' migration percentage (MP) was measured. In the three hips that underwent pelvic (Dega) osteotomy, the acetabular index (AI) was also measured. A paired t-test for non-parametric data was used to determine statistical significance.

Results: At an average of 8 months follow up, the pre-op MP had reduced from 64% to 23.3% ($p=0.026$). In the hips who had Dega osteotomy, the AI went down from 33.3 degrees to 23.3 degrees ($p=0.013$) at an average of 5 months follow up.

Conclusion: In the absence of a blade plate, the novel technique described is an effective alternative in performing VDRO surgery.

Keywords: Varus derotation osteotomy, VDRO, Neuromuscular hip, Hip dysplasia, Cerebral palsy, Hip surgery

Introduction

Hip dysplasia afflicts up to 33% of children with neuromuscular disease, with greater occurrence in those with more severe disease involvement [1]. Higher Gross Motor Function Classification System (GMFCS) scores are associated with hip subluxation and dislocation [2, 3]. Radiographic percentage of the femoral head uncovered by the acetabulum is measured using Reimers' migration percentage (MP) [4]. When the MP exceeds 30% there is an increased risk of progression and when it exceeds 60% the hip is considered at risk of dislocation [5].

The main objective of treatment is improving coverage of the hip to prevent dislocation and aid normal development. Depending on the degree of dysplasia, the treatment required may range from casting in abduction, adductor tenotomy and proximal femur osteotomy, to salvage procedures including excision arthroplasty. The surgical procedure most often required to improve positioning of the hips is a varus derotation osteotomy (VDRO), occasionally with a pelvic osteotomy [6, 7]. VDRO is usually undertaken using a fixed angle blade plate (Fig. 1 & 2). These implants are used in conjunction with bespoke sets and are not always readily

Submitted: 21/06/2024; Reviewed: 18/07/2024; Accepted: 27/05/2025; Published: 10/08/2025

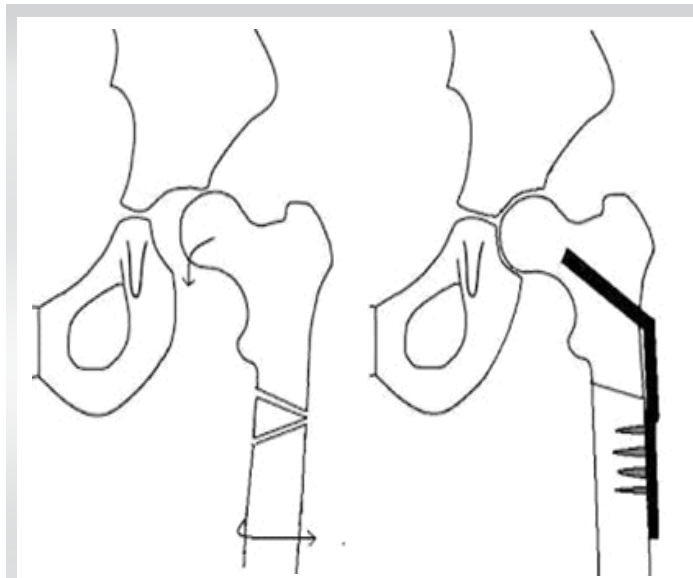


Figure 1: Diagram of a proximal femoral varus osteotomy. **Figure 2:** Drawing of fixation of osteotomy with a blade plate. (Figure 1, 2 Courtesy of BC Children's Hospital, Vancouver, Canada)

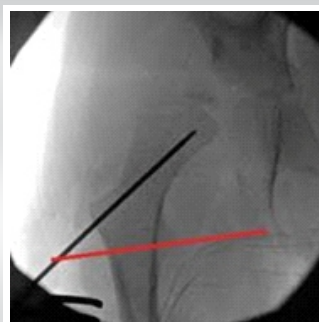


Figure 3: 2 mm guide wire placed up the femoral neck

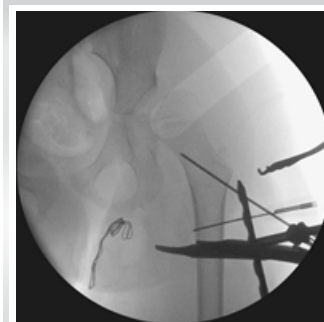

Figure 4: Suspension of most proximal hole of plate on wire and marking of the femur just distal to the second hole

available, especially in resource limited settings [8]. We therefore developed a novel technique using a locally available locking reconstruction plate to perform VDRO surgery. We measured efficacy using MP, and, where a pelvic osteotomy was performed, the acetabular index.

Surgical Technique

The child under general anaesthesia is placed supine, the affected side tilted up with a bump underneath the lower thorax. In cases of bilateral hip surgery, the bump is placed underneath the thoraco-lumbar spine. With use of the image intensifier, the ability to reduce the hip is determined by abduction. If reduction is not possible, then the patient is prepped and draped. Often the adductors are tight and an adductor tenotomy was undertaken. If the hips are not fully reducible, an anterior approach to the hip is used to expose the joint, clear the acetabulum of any obstructing soft tissue, imbricate the capsule and the hip held in abduction.

Next, a separate incision is made along the lateral thigh, the fascia lata incised and the vastus lateralis elevated or split to access the proximal femur. A guidewire (2 mm K-wire) is inserted up the centre of the femoral neck (Fig. 3). The proximal hole of a small fragment reconstruction locking plate is suspended on this guidewire and a mark made distal to the second hole. A medial closing wedge osteotomy is then carried out in the subtrochanteric region, with care taken not to extend the proximal limb of the osteotomy proximal to the mark (Fig. 4 and 5). The excised wedge of bone is preserved for the pelvic osteotomy. The bones are apposed, the femoral shaft slightly medialised if possible, and the plate applied with the K-wire in situ.

Frequently, gentle contouring is required to ensure the plate approximated well to the bone and the shaft sufficiently medialised. The plate is clamped on to the distal fragment with bone reduction forceps and images are taken to ensure the hip is in varus and well reduced. The distal fragment is often externally rotated to correct frequently occurring femoral anteversion.

The second most proximal hole of the plate is secured to the proximal fragment with a 3.5 mm locking screw. The guidewire is replaced with a long cancellous screw. After final adjustments to the rotation and bone apposition, the femoral shaft screws are inserted (Fig. 6 and 7). If the acetabulum is dysplastic, a

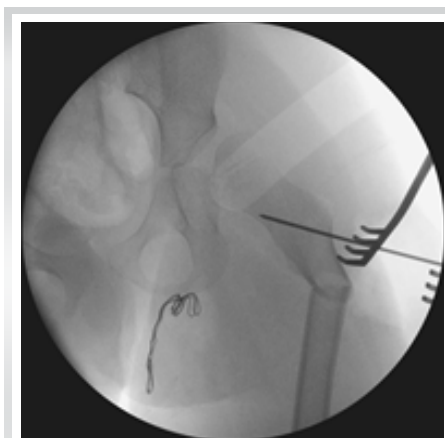

Figure 5: Apposition of bones after medial wedge closing osteotomy of proximal femur

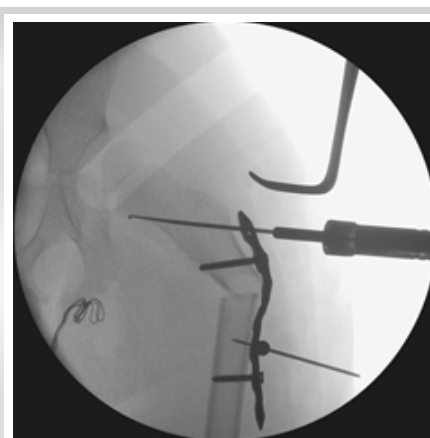


Figure 6: Securing of reconstruction plate to bone

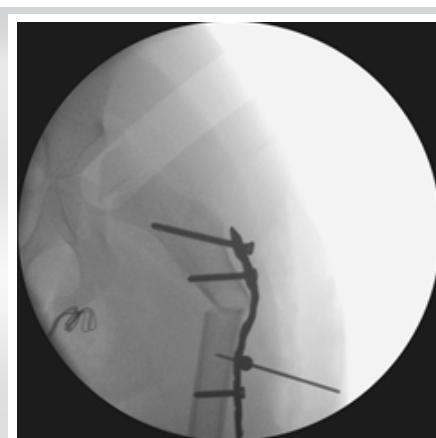

Figure 7: Insertion of long cancellous screw in most proximal hole of plate

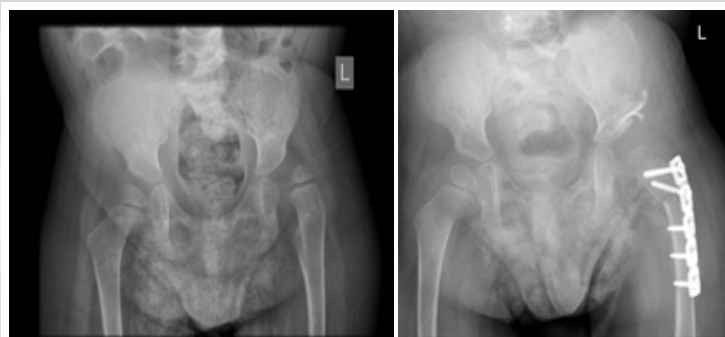


Figure 8: Preoperative images on the left, and postoperative on the right

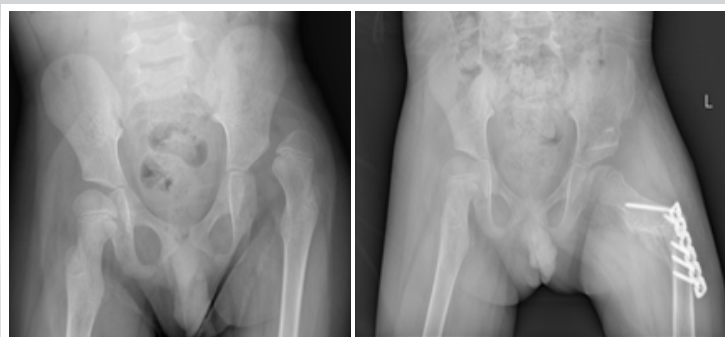


Figure 9: Preoperative images on the left, and postoperative on the right

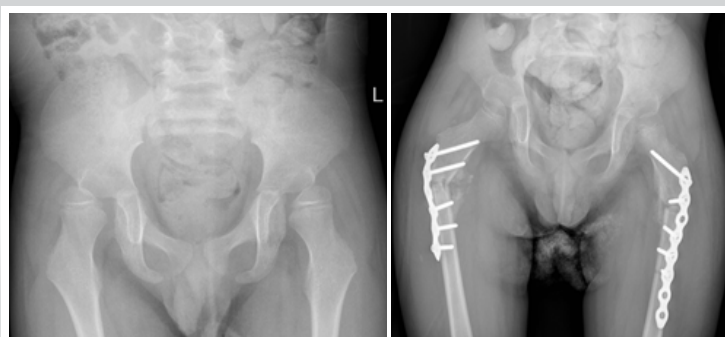


Figure 10: Preoperative images on the left, and postoperative on the right

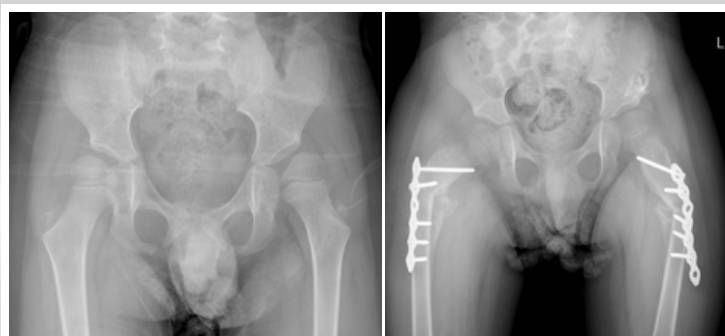


Figure 11: Preoperative images on the left, and postoperative on the right

Dega pelvic osteotomy is performed. The wedge of bone from the femur is impacted into the osteotomy site without additional fixation. After washout and closure, a hip spica is applied for four weeks.

Methods

Following institutional Research Ethics Board approval, we

reviewed six hip in four patients, all GMFCS IV or V, who had undergone VDRO surgery using the above method between October 2021 and January 2023 with a view to determining the change in MP, and in those who had pelvic osteotomy, the acetabular index, using antero-posterior radiographic views of the pelvis (Fig. 8-11). A paired t-test for non-parametric data was used to determine statistical significance.

Results

Table 1: Reimers migration percentage (MP)

Hip	Pre-op MP	Post-op MP	Follow up (months)
1	>100%	50%	3
2	>100%	0%	11
3	60%	16%	16
4	36%	29%	16
5	42%	18%	1
6	51%	27%	1
Average	64%	23.30%	8

Table 2: Acetabular index (AI)

Hip	Pre-op AI (degrees)	Post-op AI	Follow up
1	35	25	3 months
2	33	25	11 months
3	n/a	n/a	-
4	n/a	n/a	-
5	n/a	n/a	-
6	32	20	1 month
Average	33.3	23.3	5 months

Statistics

Table 3: Reimers Index

	Mean	Standard Deviation	
Pre-op	64.83%	28.43	
Post-op	23.33%	16.63	
Paired Differences	Mean	Standard Deviation	P Value
Pre-op - Post-op	41.5	32.57	0.026

Table 4: Acetabular index

	Mean	Standard Deviation	
Pre-op	33.33	1.53	
Post-op	23.33	2.89	
Paired Differences	Mean	Standard Deviation	P Value
Pre-op - Post-op	10	2	0.013

D
i
s
c
u
s
s
i
o
n
V
D
R
O

using an appropriately contoured locking plate has proved to be an adequate implant in maintaining bony apposition and may be considered in cases where a blade plate is not readily available. The technique does have a learning curve and requires a trained assistant. One of the difficulties in using this technique compared to a standard blade plate is its inability to obtain sufficient varus. The skill of the assistant is essential in holding the osteotomised bony fragments in the desired position long enough for the surgeon to adequately contour and apply the plate.

We observed that the plate was not always flush against the bone but as there is sufficient soft tissue cover and additional stability from the hip spica, this is rarely a clinical concern, though there is the potential for prominent metalwork in children with poor soft tissue coverage around the proximal lateral thigh. There is the potential for prominent metalwork in children with poor soft tissue cover over the hip. Adequate plate contouring helps to minimise this problem. Achieving medialisation of the shaft is an additional concern with this technique, though this is not of critical concern in non-walking patients (GMFCS levels IV and V).

The implant should be durable to hold the fragments but malleable enough to be contoured. We found that the 6-hole, 3.5 mm AO-type reconstruction locking plate was suitable. The proximal screw that replaces the 2 mm guide-wire may not provide ideal purchase, so great care should be taken to ensure that the second screw hole is not unnecessarily tampered with during the contouring, as this will be the only locking hole in the proximal fragment.

Post-operatively, a hip spica is recommended to ensure the femoral head is well placed within the acetabulum, to reduce the strain on the metalwork and to prevent re-contraction of the adductors in the short term. The hip spica can be removed after 4 weeks once the osteotomy is consolidating and replaced with a hip abduction brace which should be worn as often as possible, in addition to the usual hip precautions of a wheelchair with a

pommel and avoidance of swaddling. Physiotherapy can resume at 2 months once the osteotomy has healed. Implant removal can be considered after 6 months.

Limb length inequality may have an impact on patients using a standing frame. This should be communicated to parents and included in the consent form. The resulting asymmetry has not been shown to have a deleterious effect on the sitting balance or function of the non-ambulatory and non-standing child [9].

We found a significant reduction in the migration percentage at follow-up, and all the osteotomy sites had healed both clinically and radiographically.

This case series highlights the improvement of femoral head coverage in VDRO surgery using a locking plate as described. Though the numbers in the study were small leading to the possibility of a Type II error, our results point towards this novel technique being a viable alternative in low-resource settings, where fixed-angle blade plates are not readily available.

Conclusion and recommendation

A well contoured 3.5 mm reconstruction plate, using the above technique, may be used as a substitute for a blade plate when performing VDRO surgery. It is not technically straightforward and there is a learning curve, but the objective of improved hip coverage can be achieved. When combined with an appropriate pelvic osteotomy, this novel method can provide adequate femoral head coverage with minimal complications.

References

- Hagglund G, Lauge-Pedersen H and Wagner P. Characteristics of children with hip displacement in cerebral palsy. *BMC Musculoskeletal Disord* 2007; 8: 101.
- Soo B, Howard JJ, Boyd RN, et al. Hip displacement in cerebral palsy. *J Bone Joint Surg Am* 2006; 88: 121–129.
- Connelly A, Flett P, Graham HK, et al. Hip surveillance in Tasmanian children with cerebral palsy. *J Paediatr Child Health* 2009; 45(7–8): 437–443.
- Reimers J. The stability of the hip in children: a radiological study of results of muscle surgery in cerebral palsy. *Acta Orthop Scand* 1980; 184: 1–100.
- Miller F and Bagg MR. Age and migration percentage as risk factors for progression in spastic hip disease. *Dev Med Child Neurol* 1995; 37(5): 449–455.
- Flynn JM and Miller F. Management of hip disorders in patients with cerebral palsy. *J Am Acad Orthop Surg* 2002; 10: 198–209.
- Bouwuis CB, van der Heijden-Maessen HC, Boldingh EJ, et al. Effectiveness of preventive and corrective surgical intervention on hip disorders in severe cerebral palsy: a systematic review. *Disabil Rehabil* 2015; 37(2): 97–105.
- Alibhai A, Hendrikse C, Bruijns SR. Poor access to acute care resources to treat major trauma in low- and middle-income settings: a self-reported survey of acute care providers. *Afr J Emerg Med*. 2019;9:S38–S42. doi: 10.1016/j.afjem.2019.01.004.
- Larsson M, Häggglund G and Wagner P. Unilateral varus osteotomy of the proximal femur in children with cerebral palsy: a five-year follow-up of the development of both hips. *J Child Orthop* 2012; 6(2): 145–151.

Declaration of patient consent : The authors certify that they have obtained all appropriate patient consent forms. In the form, the patient has given the consent for his/ her images and other clinical information to be reported in the journal. The patient understands that his/ her names and initials will not be published and due efforts will be made to conceal their identity, but anonymity cannot be guaranteed.

Conflict of interest: Nil **Source of support:** None

How to Cite this Article

Baraza N, Ating'a M. Varus Derotation Osteotomy of the Proximal Femur in Neuromuscular Children Using a Locking Plate-Surgical Technique and Initial Results. International Journal of Paediatric Orthopaedics . May-August 2025; 11(2):16-20.